

# Patient Information Sheet

## HIP OSTEOARTHRITIS

### Structure

The hip joint lies between the pelvic bone (*pelvis*) and thigh bone (*femur*). The ball at the top of the thigh bone (*femoral head*) fits into the cup-like socket on the side of the pelvis (*acetabulum*). The hip joint has a large range of motion and is very stable because of the shape of the ball and socket joint. The hip is bent (*flexed*) by the groin muscles (*ilio-psoas / rectus femoris*) and straightened (*extended*) by the buttock muscles. The pelvis stays level when standing on one leg whilst walking because of contraction of the strong hip *abductor* muscles lying deep in the buttock. Strong hip abductors are essential for normal walking. Covering the ends of the ball and socket is a tough low friction surface (*articular cartilage*). This surface transfers load from the body to the lower limb.

### Function

Articular cartilage consists of cells (*chondrocytes*) that produce fibres (*collagen*) and a gel. The fibre-gel is known as the *matrix*. This gel consists of large negatively charged molecules (*proteoglycans*) that attract positively charged water ions to 'blow up' (*hydrate*) the gel. This fibre-reinforced composite gel efficiently resists compression and provides an almost frictionless gliding surface for movement.

Biochemically, large proteoglycan molecules consist of a hyaluronic acid backbone with proteoglycan monomer side chains. Hyaluronic acid contains *glucosamine* whilst proteoglycan monomers contain *chondroitin* sulphate. Glucosamine and chondroitin are two 'building blocks' of articular cartilage which is why they are used in some arthritis medications.

### Failure

The ability of the hip joint to efficiently transfer load to the lower limb is determined by the quality of the matrix produced by chondrocytes. Young normal chondrocytes produce high quality matrix that easily transfers load without damaging the joint surface. However, older or injured chondrocytes produce lower quality matrix that may be damaged with normal hip use. This causes cartilage surface "wear and tear" resulting in degenerative joint disease (also called osteoarthritis or OA). OA is classified as primary age-related or secondary post-traumatic. Primary (or constitutional) OA is part of the normal aging process and begins in the 40s. Secondary OA results from a joint injury or fracture resulting in a "step" in the normally smooth joint surface which rapidly wears out with normal hip use.

### Diagnosis

OA is diagnosed by the history of a gradual onset of pain often persisting at night. Other symptoms include stiffness (difficulty reaching the shoes and socks) and reduced walking ability. Examination indicates a painful walking pattern (*antalgic gait*), pelvic tilting when standing on one leg (*abductor weakness*) and a restricted range of motion. X-ray shows reduced joint space, bone overgrowth (*osteophytes*), hardening (*sclerosis*) and cyst formation.

### Management

Initially a trial of activity modification, weight loss, walking aid use, physiotherapy, anti-inflammatory medication and glucosamine is undertaken. Once non-operative management has failed total joint replacement (*arthroplasty*) is performed.

#### SYDNEY CBD

mi-Clinic  
Level 2  
44 Market St  
Sydney NSW 2000

#### SAN CLINIC

Suite 601  
Sydney Adventist Hospital  
185 Fox Valley Rd  
Wahroonga NSW 2076

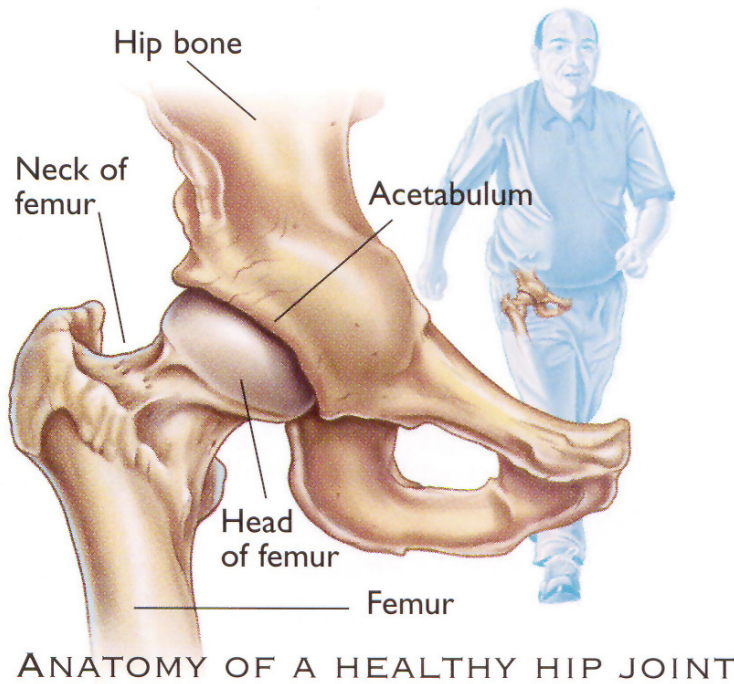
Ph 9473 8648

[www.nigelhope.com.au](http://www.nigelhope.com.au)

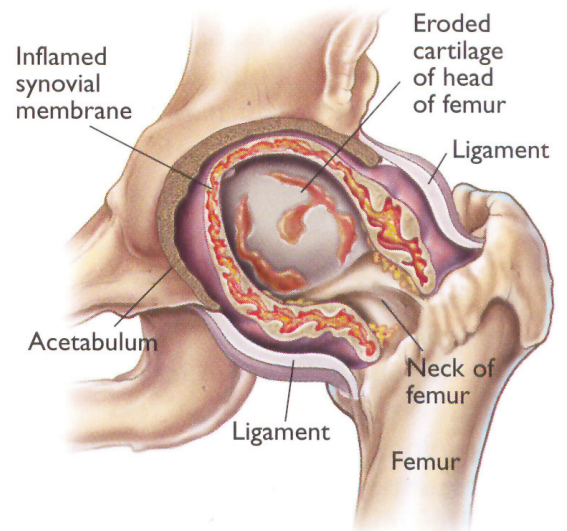
Correspondence to SAN CLINIC

# Patient Information Sheet

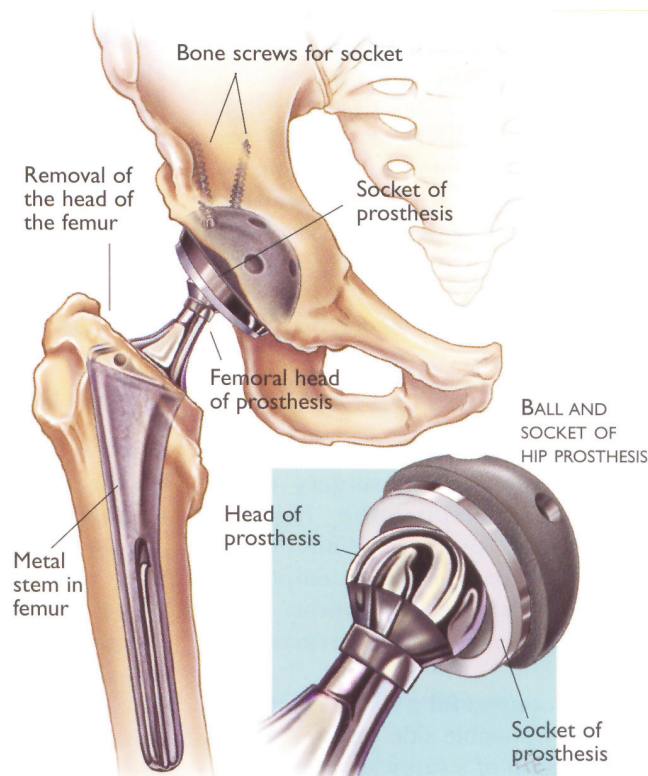
## HIP OSTEOARTHRITIS



### DISEASED HIP JOINT



Cross-section of a hip joint with advanced rheumatoid arthritis. The diseased bone and cartilage shows why hip movement becomes limited and painful.



## Total Hip Replacement